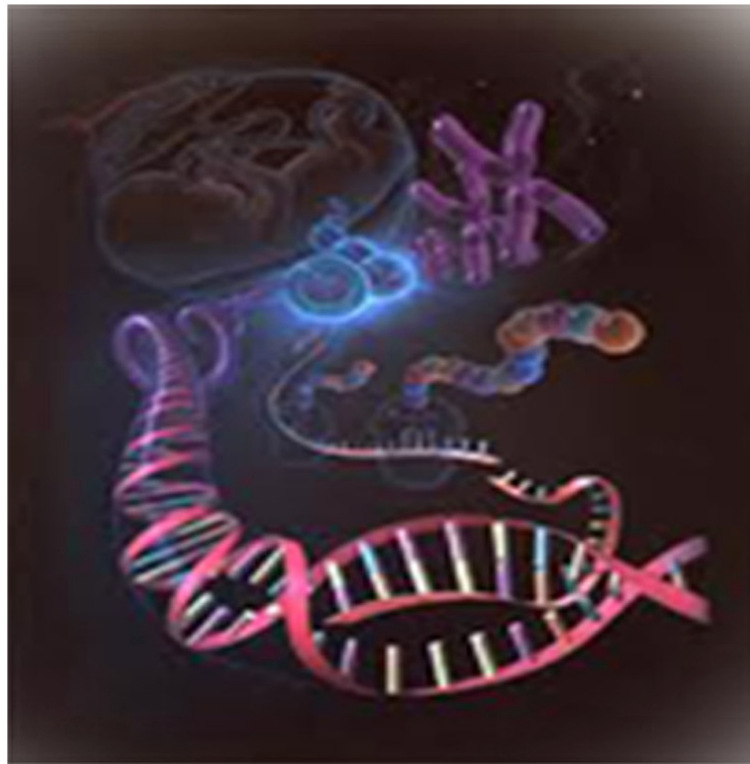




International Journal of Life Sciences Biotechnology and Pharma Research





Research Paper

AN UNUSUAL TORTUOUS BRACHIAL ARTERY AND ITS BRANCHES: HISTOLOGICAL BASIS AND ITS CLINICAL PERSPECTIVE

Ashwini C^{1*} and Vasantha Kuberappa²

*Corresponding Author: **Ashwini C** ✉ meashumbbs@gmail.com

The arteries of upper limb was studied in 50 cadavers which were dissected by Medical, Dental, and Ayurvedic students in Department of Anatomy, JSS Medical College, Mysore over a period of 3 years 2009-2011. The arteries in 49 cadaveric specimen showed the normal arterial configuration. In one cadaver the course of the artery was anomalous. It showed an unusual tortuous course with loops and bends. Tortuous peripheral arteries are usually asymptomatic. An abnormal superficial tortuous brachial artery and its branches may be mistaken for basilic vein during cannulation. It may also be a cause for focal peripheral neuropathy. Tortuous radial artery is one of the cause for failure of transradial coronary procedure and complications. The clinical importance of the described variation is of utmost significance for surgeons, cardiologists and vascular specialists.

Keywords: Brachial artery, Tortuosity, Loops

INTRODUCTION

The normal gross anatomy of the brachial artery in man is well documented in all textbooks of anatomy. It arises as a continuation of the axillary artery at the lower border of the teres major and terminates usually at the neck of the radius by dividing into radial and ulnar artery (Bin N *et al.*, 2009).

The present paper reports on the tortuous course of the brachial, radial and ulnar arteries which was observed in one of the cadaver in department of anatomy, JSS Medical College, Mysore.

Anomalies in the brachial artery are generally centered on its anomalous origin and its branches. Tortuosity of the individual artery is not a rare entity. But bilateral involvement and generalized tortuosity of artery is rare (Cheng C H *et al.*, 2009).

Individual vessel tortuosity and aneurysms have been seen in patients with atherosclerosis, hypertension, diabetes and obesity. It is also seen in patients suffering from connective tissue disorders due to genetic defect in elastogenesis or collagen synthesis.

¹ Department of Anatomy, Mysore Medical College and Research Institute, Mysore.

² Department of Anatomy, Shimoga Institute of Medical Sciences, Shimoga.

Radial artery loops or tortuosity has been described because of failure in transradial coronary procedure. Brachial artery tortuosity is rare because of its large diameter. Here we describe a case of tortuosity of the brachial and its branches.

MATERIALS AND METHODS

The arteries of upper limb was studied in 50 cadavers which were dissected by Medical, Dental, and Ayurvedic students in Department of Anatomy, JSS Medical College, Mysore over a period of 3 years 2009-2011.

The brachial artery was exposed after the skin and cutting through the deep fascia on the anterior surface of the arm. Neurovascular bundle of the arm is found immediately deep to the deep fascia and medial to biceps. Brachial artery was traced proximally into continuity with axillary artery in the axilla and distally to the level of elbow where it divides into radial and ulnar arteries.

A small piece of tissue was taken from an anomalous brachial artery for histopathological study and also serial sections were processed for special stains for elastic and collagen fibres (Verhoeff- Vangieson's stain).

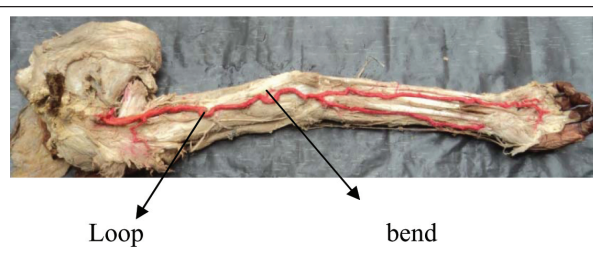
Observation and Results

The arteries in 49 cadavers showed the normal arterial configuration. In one cadaver the course of the artery was anomalous. It showed an unusual tortuous course with loops and bends.

The tortuosity was predominant on the right side of the upper limb.

We could observe two loops in a brachial artery which were very prominent than the loops present in the radial and ulnar artery (Figure1). Tortuosity was noted only in the brachial artery and its branches. Axillary artery and other major arteries were normal in appearance.

Figure 1: Tortuous Arteries of Upper Limb



On H&E staining, the tunica media showed a large bundles of smooth muscles which are longitudinally arranged. On special staining the number of collagen and elastic fibres distributed in the artery was decreased. Other relevant finding of the arterial biopsy was a decrease of the external elastic membrane and fragmentation of the internal elastic membrane.

DISCUSSION

Tortuosity can be defined as presence of a bend or angulation of more than 45° to 90° . Tortuosity of the artery is a rare morphologic entity, more frequently described in internal carotid artery as this has been related to cranial nerve or brainstem dysfunction.

Etiology for the tortuosity of artery has been said due to abnormal elastogenesis.

In the study done by Cheng CH et al on mice they have described mutations in the SLC2A10 gene which encodes for GLUT10 causes arterial tortuosity syndrome in humans.

The upregulation of TGF beta signaling pathway is involved in elastogenesis and has been described in arterial tortuosity syndrome. Other clinical features of arterial tortuosity syndrome include aneurysm, stenosis, & laxity in skin and joints.

Contrary to the animal study done by Cheng C H *et al.*, we found there was normal

configuration of elastic fiber in the tortuous brachial artery but the number elastic fiber was decreased. Longitudinal smooth bundle are more in number which is unusual in the peripheral arteries

Arterial tortuosity syndrome is an autosomal recessive disorder with typical features compressing tortuosity and elongation in the major vessels due to disorganization of elastic fibres in the arterial wall

Ertrugul Ali describes a case of 10 year old girl all of whose major arteries-the carotids, aorta, the iliac, femoral, splenic, hepatic, renal, and intercostal arteries-were tortuous and lengthened. On arterial biopsy they have also observed there decreased elastic tissue in tunica media and break down of elastic lamina.

There is a chance of breakdown of the elastic lamina with age. The fragmentation and calcification of the arterial elastic tissue is also possible with increasing age. In addition, it has been demonstrated that calcification of the medial elastic tissue does not depend on a pre-existing arteriosclerosis.

In a clinical study done on Chinese population with a sample of 3000 cases, they found anatomic variations in arteries of upper limb in 610 cases. Among 610 cases, they found tortuous radial artery in 150 cases, brachial artery in 27 and tortuous subclavian artery in 57 cases.

Lo T S *et al.* has studied 1540 patients for a radial artery anomaly, among which only 35 had a full radial loop and 30 had extreme radial tortuosity.

Tortuous peripheral arteries are usually asymptomatic. An abnormal superficial tortuous brachial artery may be mistaken for basilic vein

during cannulation. It may also be a cause for focal peripheral neuropathy. Tortuous radial artery is one of the cause for failure of transradial coronary procedure and complications. In this cadaver we observed loops and acute bends which may result in occlusion causing ischemia. The clinical importance of the described variation is of utmost significance for surgeons, cardiologists and vascular specialists.

CONCLUSION

Tortuosity of the artery is a rare entity, which is important for clinicians to have knowledge before they do procedure like cannulation, angiography or arteriography.

ACKNOWLEDGMENT

Author extends sincere thanks to the department of pathology, JSS medical college, Mysore for their kind support during this study.

REFERENCES

1. Bin N, Yu-jie Z, Guo zhong L I, Dong-mei Shi, Jian-long Wang (2009), "Clinical study of arterial anatomic variations for transradial coronary procedure in Chinese population", *Chin Med J.*, Vol. 122, No. 18, pp. 2097-2102.
2. Cheng C H, Kikuchi T, Chen Y H, Lee Y C, Pan H J and Chang C *et al.* (2009), "Mutations in the SLC2A10 gene cause arterial abnormalities in mice", *Cardiovascular Research*, Vol. 81, pp. 381-388.
3. Ertrugul A (1967), *Circulation-Journal of American heart association*, Vol. 36, pp. 400-407.
4. Lo T S, Nolan J, Fountzopoulos E, Behan M, Butler R, Hetherington S L *et al.* (2009),

“Radial artery anomaly and its influence on transradial coronary procedural outcome”, *Heart*, Vol. 95, No. 5, pp. 410-415.

5. William P L, Bannister L H and Berry M M *et al.* (1995), 38th Edition, Gray's Anatomy, New York, Churchill Livingston, pp. 318-320.

